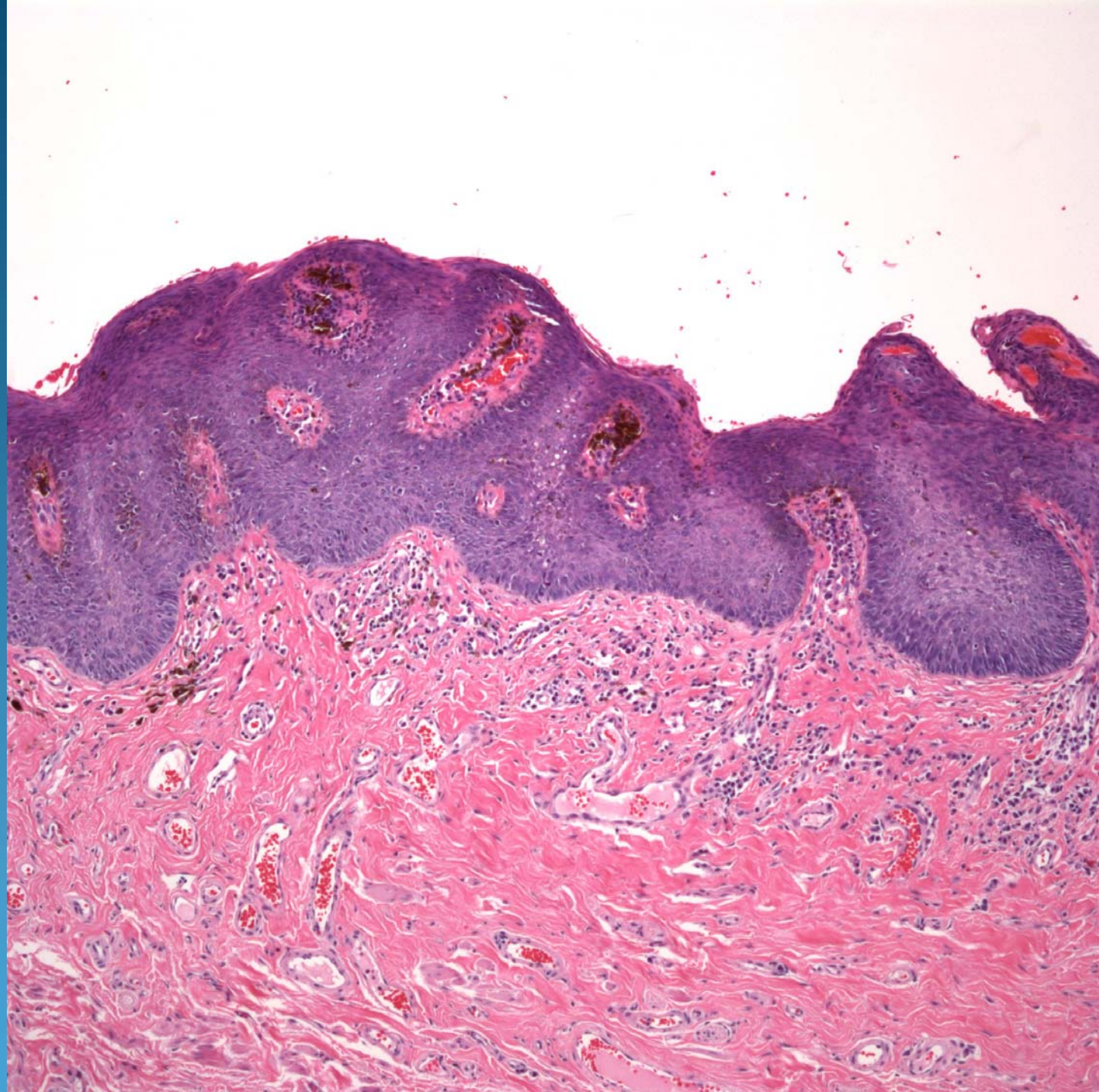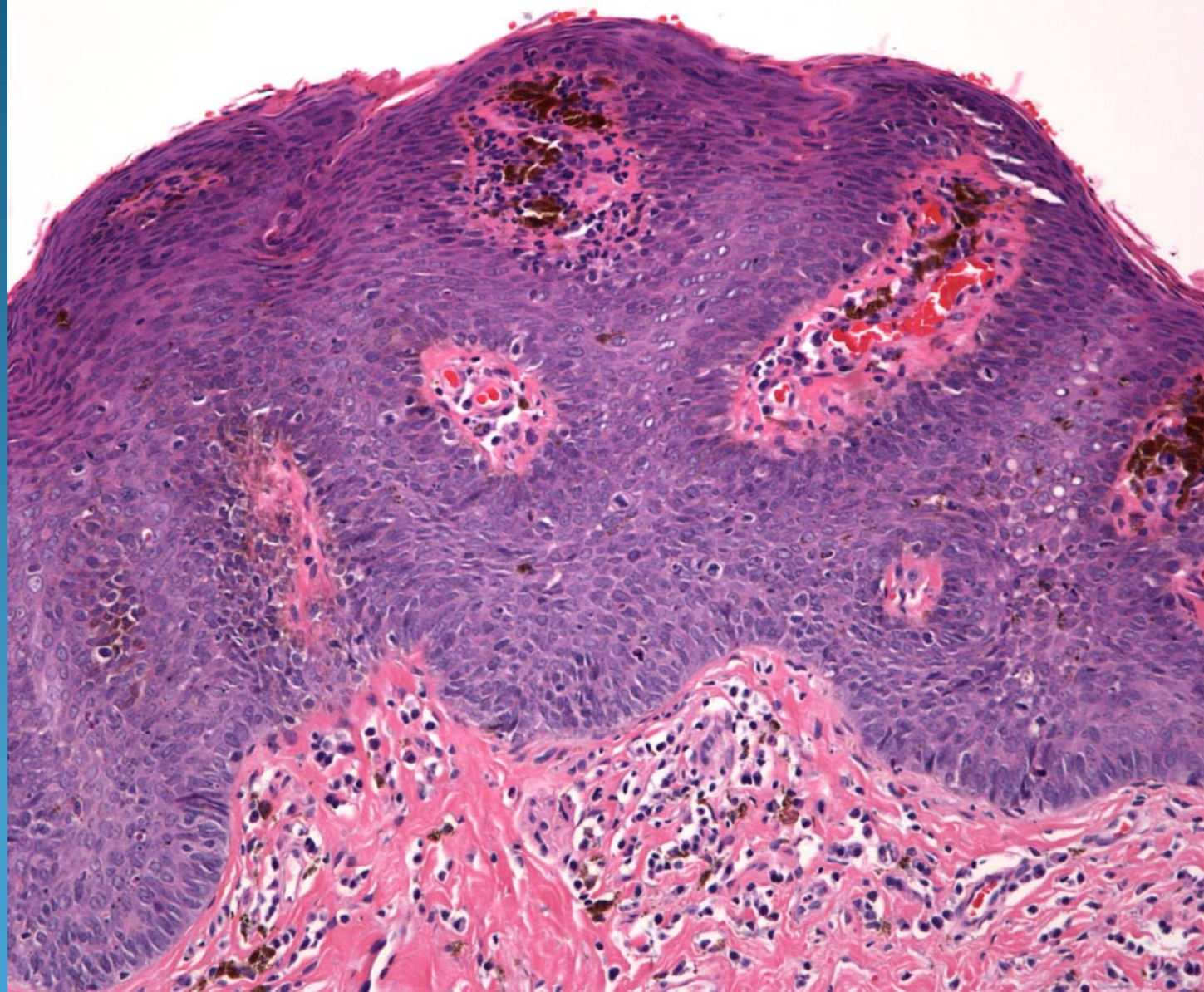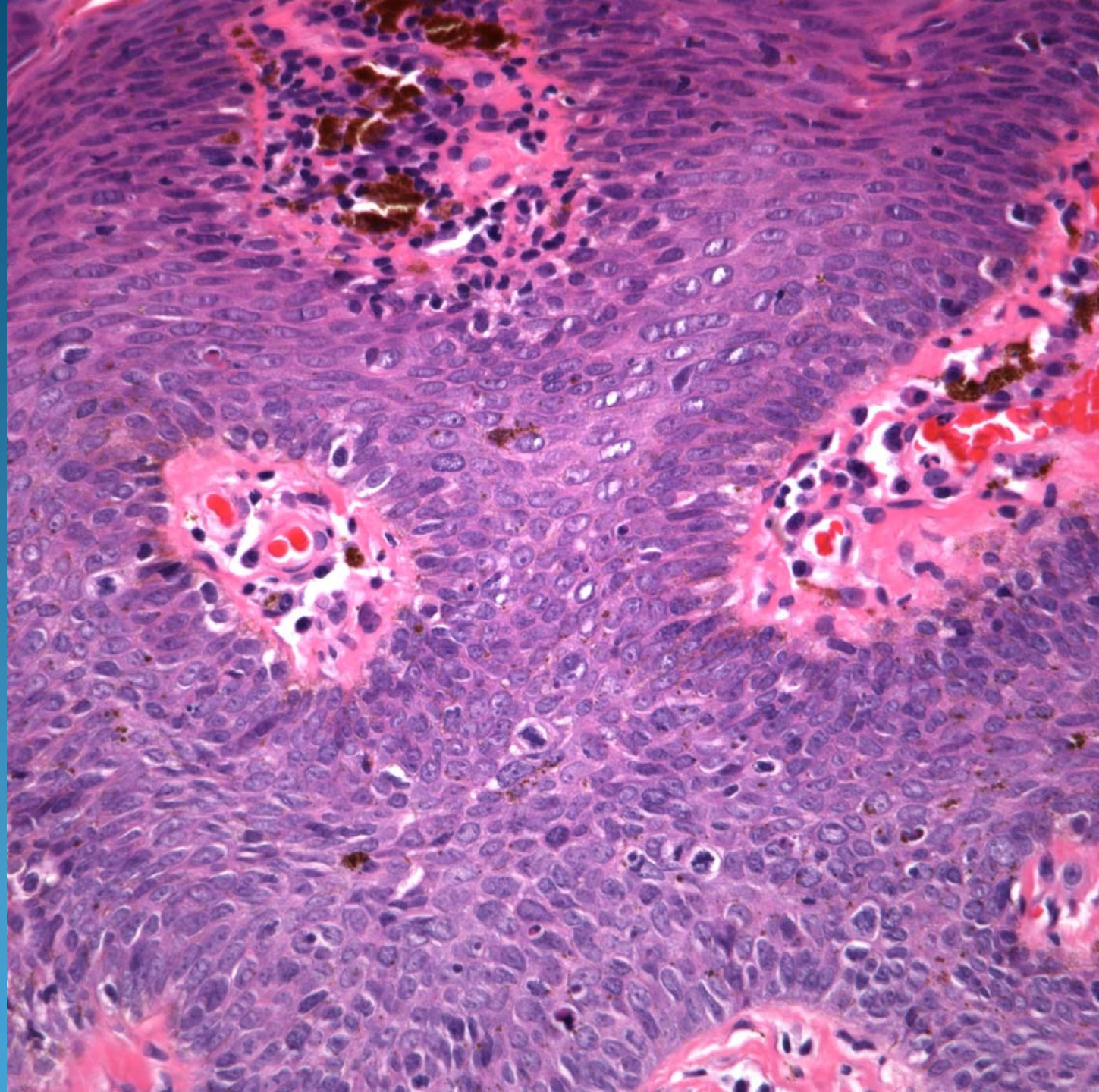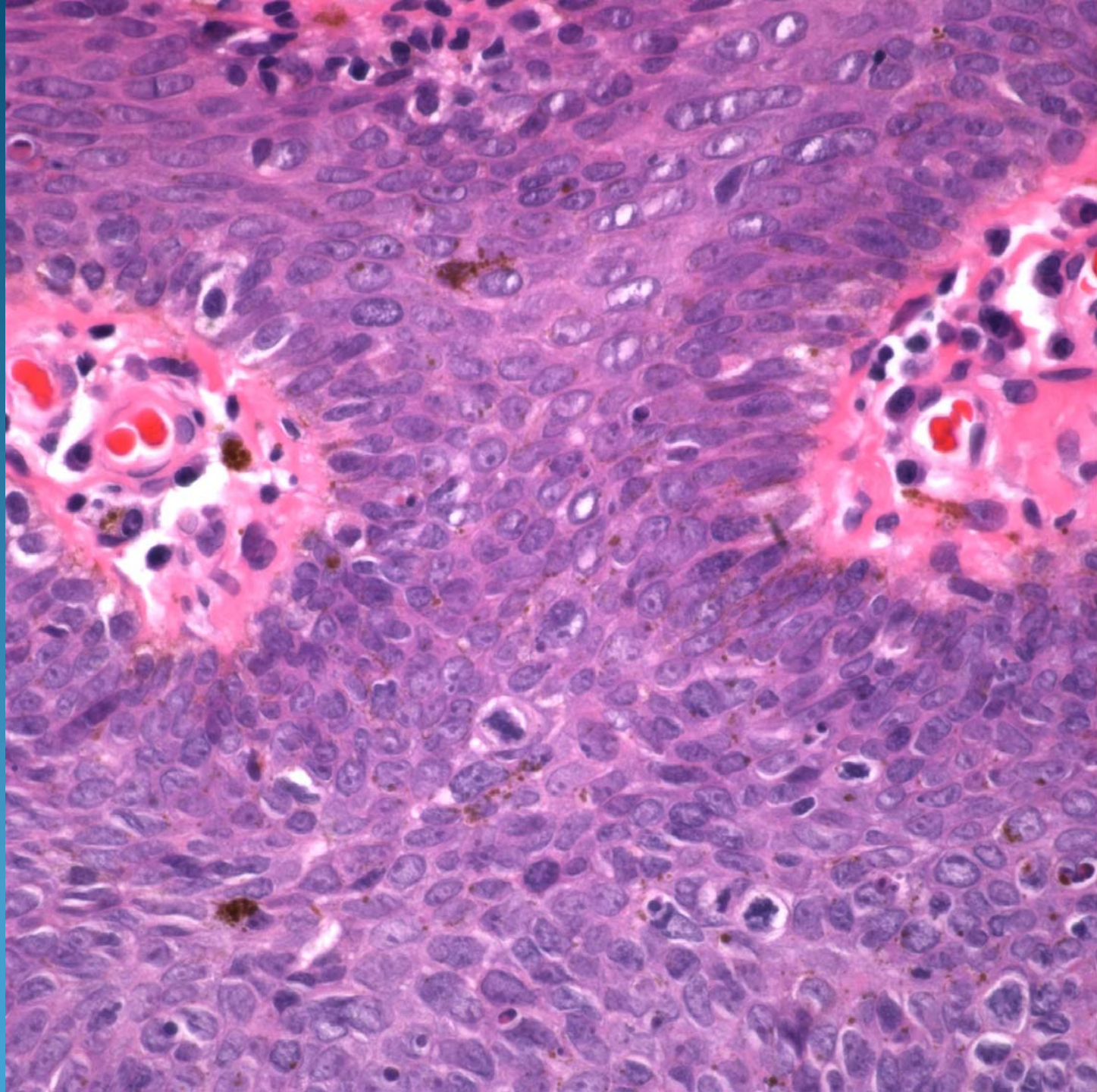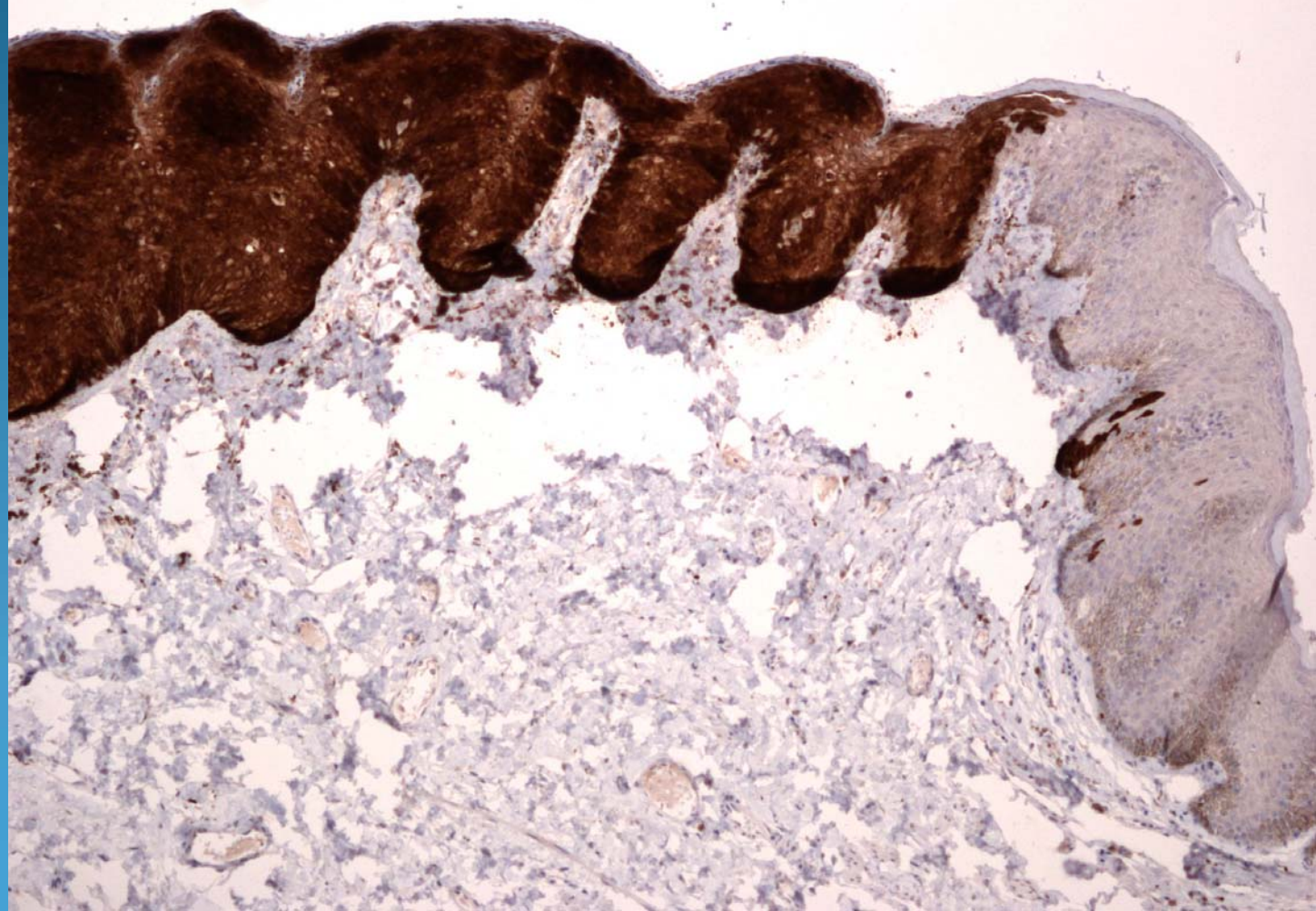
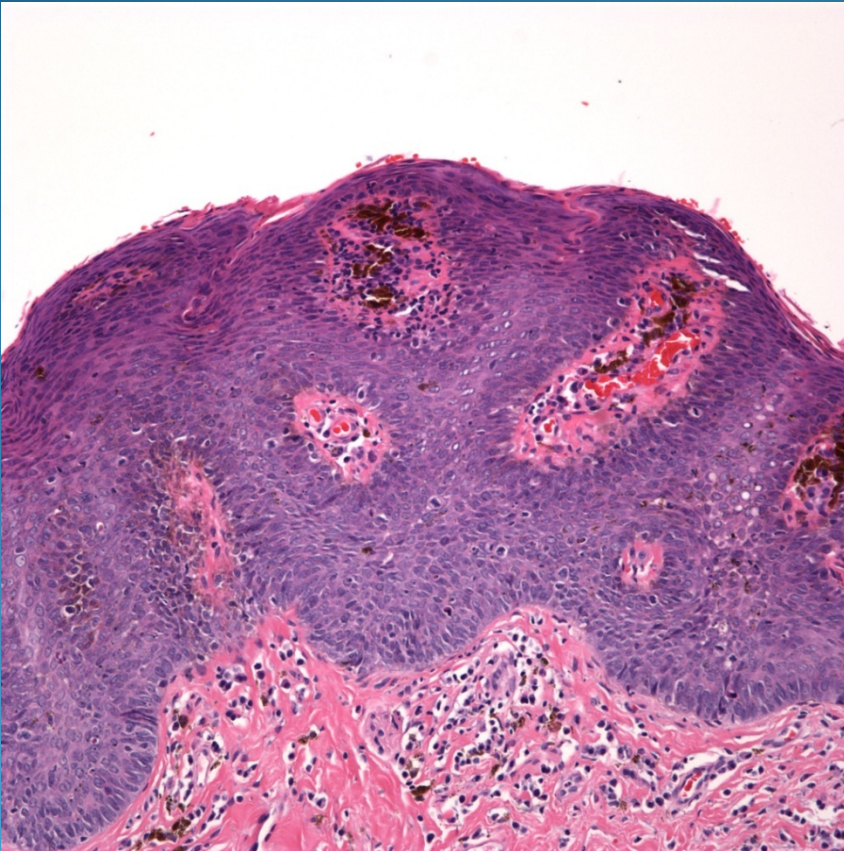


p16



Erythroplasia of Queyrat (Bowen's disease of the glans penis)

Pearls



- Characteristic location
- Full thickness replacement of squamous mucosa by cytologically atypical squamous epithelial cells
- Loss of polarity, atypical mitotic figures, dyskeratosis
- Many cases p16+ indicative of high risk HPV infection